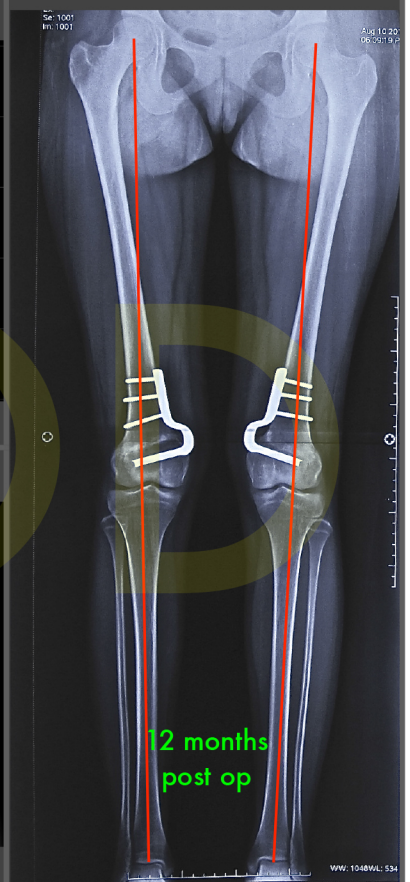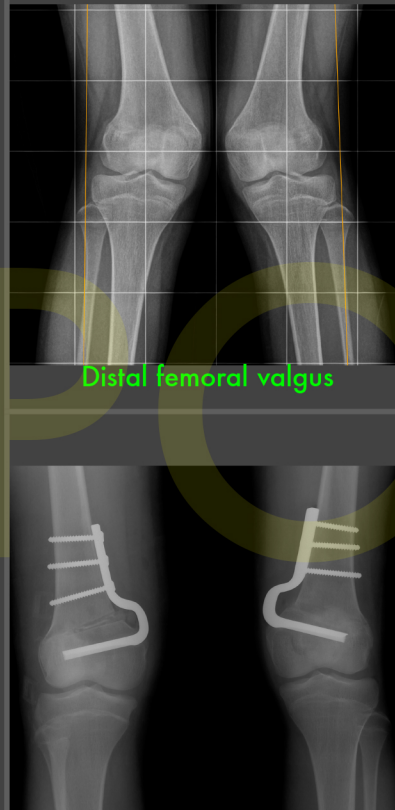
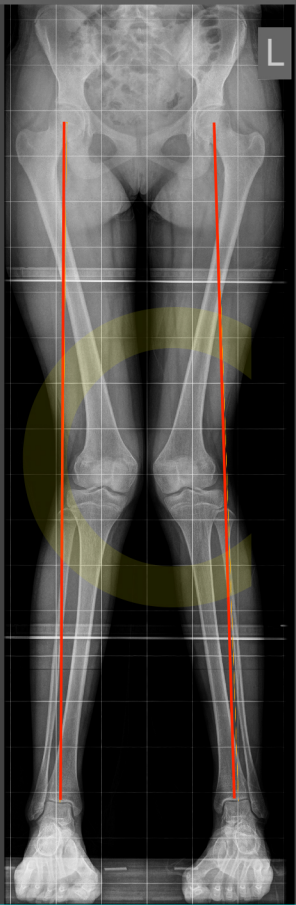


DEFORMITY CORRECTION

14 year old
Genu valgum
No underlying
metabolic
disease



16 year old
Genu valgum
Failed staple
hemi
epiphysiodesis
Single stage
correction of
deformity and
restoration of
alignment

